

Available online at [www.sciencedirect.com](http://www.sciencedirect.com)

SciVerse ScienceDirect

British Journal of Oral and Maxillofacial Surgery xxx (2016) xxx-xxx

BRITISH  
Journal of  
Oral and  
Maxillofacial  
Surgery[www.bjoms.com](http://www.bjoms.com)

## Letter to the Editor

### Conjunctival chemosis: an uncommon complication after transcresal lifting of the sinus floor

Sir,

Conjunctival chemosis is non-specific oedema, which may be caused by many systemic and local factors, including allergies; bacterial, viral, and mycotic infections; autoimmune diseases; thyroid disorders; and neoplasms. The orbit is susceptible to the contiguous spread of infections from the maxillary sinus as they are separated only by a thin plate of bone, which could also have congenital bony dehiscences. These infections may then cause complications, which have been categorised by Chandler et al,<sup>1</sup> into five stages, according to severity.

A 47-year-old woman presented with no systemic complaints or abnormalities of the sinuses. After performing a crestal access with ultrasonic instruments, we used hydrodynamic pressure to raise the Schneiderian membrane. There were no perforations or any other intraoperative complications, so we inserted a xenogeneic graft and two dental implants. She was given antibiotics and non-steroidal anti-inflammatory drugs for one week. At the follow-up visit 8 days later, she had considerable conjunctival oedema (Fig. 1), which had begun the day before. She had no clinical signs of sinusitis and the wound was healing well. We did cone-beam computed tomography (CBCT), which showed mucosal thickening that obstructed the right maxillary sinus cavity completely, with a patent ostium (Fig. 2). We consulted an ophthalmologist, who diagnosed a grade 2 conjunctival

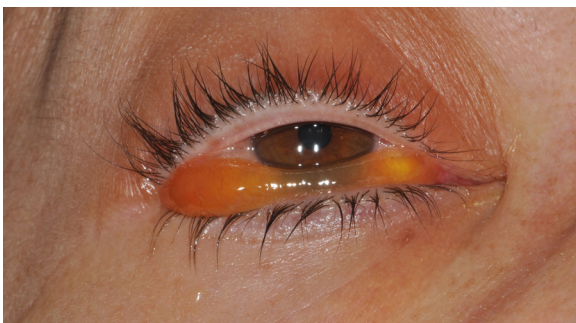


Fig. 1. Conjunctival chemosis 7 days after the lifting of the sinus floor.

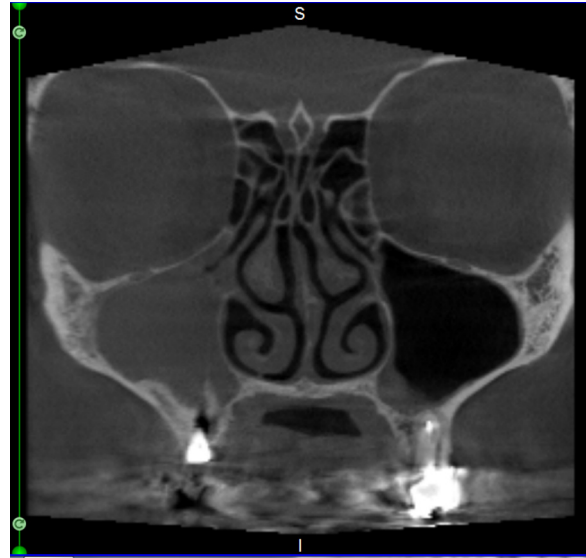


Fig. 2. Cone-beam computed tomogram taken 7 days after operation, which shows mucosal thickening completely obstructing the right maxillary sinus cavity, with a patent ostium.

chemosis<sup>2</sup> with epiphora, but the patient had no impairment of vision, proptosis, limitation of eye movement, or pain. She was treated with antibiotics, cold compresses, and steroid eye drops, and the chemosis had healed completely after 10 days. Six months later, the mucosa of the sinus looked normal on cone-beam CT examination and the implants were integrated.

Normal mucociliary clearance is the key for maintaining the health and protection of the sinuses and this is possible only if there is appropriate ciliary movement. When we raised the Schneiderian membrane, it may have transiently and unpredictably inhibited ciliary activity, and also because of bacterial infections,<sup>3</sup> could have led to thickening of the mucosa and difficulties in clearing mucus. It should be assumed that every procedure to lift the sinus could temporarily impair homeostasis of the maxillary sinus, and could cause bacterial sinusitis, which, in particular conditions, could spread to the orbit by direct extension.

Even if multiple case reports describe orbital cellulitis from an odontogenic source,<sup>4</sup> evidence of orbital involvement immediately after the lifting of the sinus floor is seldom documented.<sup>5</sup> This uncommon condition could be classified

<http://dx.doi.org/10.1016/j.bjoms.2016.02.019>

0266-4356/© 2016 The British Association of Oral and Maxillofacial Surgeons. Published by Elsevier Ltd. All rights reserved.

between Chandler class I (preseptal cellulitis without conjunctival chemosis) and class II (orbital cellulitis), because there was no proptosis or reduced ocular mobility with pain, which are pathognomonic for orbital cellulitis. The two consecutive cycles of antibiotics possibly had a key role in controlling the infection.

Follow-up visits after the lifting of the sinus floor should continue after the removal of sutures, to intercept early pathological changes, and the patient must be warned to report these immediately during healing. Collaboration between the otolaryngologist and the ophthalmologist is necessary for the optimal management of complications.

### Conflict of interest

We have no conflicts of interest.

### Ethics Statement/Confirmation of patient permission

No ethical approval was necessary. We had written consent from the patient for the use of visual images.

### References

1. Chandler JR, Langenbrunner DJ, Stevens ER. The pathogenesis of orbital complications in acute sinusitis. *Laryngoscope* 1970;**80**:1414–28.
2. Dolman PJ, Rootman J. VISA Classification for Graves orbitopathy. *Ophthalm Plast Reconstr Surg* 2006;**22**:319–24.
3. Mantovani M. Otorhinolaryngological contraindications in augmentation of the maxillary sinus. In: Testori T, Del Fabbro M, Weinstein R, Wallace SS, editors. *Maxillary sinus surgery and alternatives in treatment*. Chicago: Quintessence; 2009. p. 23.
4. Youssef OH, Stefanyszyn MA, Bilyk JR. Odontogenic orbital cellulitis. *Ophthalm Plast Reconstr Surg* 2008;**24**:29–35.
5. Chanavaz M. Sinus graft procedures and implant dentistry: a review of 21 years of surgical experience (1979–2000). *Implant Dent* 2000;**9**:197–206.

Claudio Stacchi <sup>a,\*</sup>

Rosario Sentineri <sup>b</sup>

Federico Berton <sup>c</sup>

Teresa Lombardi <sup>d</sup>

<sup>a</sup> Adjunct Professor, Department of Medical, Surgical and Health Sciences, University of Trieste, Italy

<sup>b</sup> Private Practice, Genova, Italy

<sup>c</sup> Research Fellow, Department of Medical, Surgical and Health Sciences, University of Trieste, Italy

<sup>d</sup> Private Practice, Cassano allo Jonio, Italy

\* Corresponding author at: Dental Sciences School, Piazza dell'Ospitale 1, 34129 Trieste, Italy.

Tel.: +0039 0481531229; fax: +0039 0481531229.

E-mail address: [claudio@stacchi.it](mailto:claudio@stacchi.it) (C. Stacchi)